

## THERAPEUTIC CHALLENGES IN A RARE CASE OF GENERALIZED GRANULOMA ANNULARE

CLAUDIA-IOANA DINCĂ\*, MIRCEA TAMPA\*,\*\*, IULIA LEULESCU\*, BIANCA STOIAN\*,  
ANA-MARIA MILEA\*, GRIGORE BĂLAN\*, SIMONA ROXANA GEORGESCU\*,\*\*

### Rezumat

Granulomul inelar generalizat este o afecțiune cutanată relativ rară, care se distinge prin apariția pe suprafața pielii a unor leziuni arcuate sau inelare ridicate, diseminate preferențial pe extremități și trunchi. Prezentăm un caz clinic al unei femei în vârstă de 63 de ani, care s-a prezentat cu plăci eritematoase, asimptomatice, inelare și arcuate, diseminate pe trunchi, membrele superioare și inferioare, cu evoluție de aproximativ 6 luni. Examenul histopatologic a relevat prezența unor granuloame caracterizate prin histiocite dispuse în palisadă în jurul zonelor de degenerare a colagenului și depunere de mucină. Pacienta este cunoscută și cu bypass coronarian și vasculită în antecedente. Deși în literatura de specialitate sunt menționate diverse opțiuni terapeutice pentru granulomul inelar generalizat, lipsa unor ghiduri standardizate este dezamăgitoare atât pentru medic, cât și pentru pacient, reflectând raritatea cazurilor raportate. Tratamentele citate anecdotic includ crioterapia, ablația cu laser, PUVA și terapia fotodinamică. La pacientul nostru, după o sesiune de crioterapie cu azot lichid care a avut un rezultat paradoxal nefavorabil, s-a inițiat tratament cu hidroxichlorchină și inhibitori topici de calcineurină, rezultând o ușoară ameliorare a leziunilor.

**Cuvinte cheie:** granulom generalizat anular, aspecte clinice, terapie modernă.

Intrat în redacție: 26.03.2026

Acceptat: 23.04.2026

### Summary

Generalized granuloma annulare is a relatively rare skin condition, which is distinguished by the appearance on the skin surface of elevated arcuate or annular lesions, preferentially disseminated on the extremities and trunk. We report a clinical case of a 63-year-old woman who presented with asymptomatic, erythematous, annular and arcuate plaques, disseminated on the trunk, upper and lower limbs, evolving for approximately 6 months. Histopathological examination revealed the presence of granulomas characterized by histiocytes arranged in a palisade around areas of collagen degeneration and mucin deposition. The patient is also known to have coronary bypass and vasculitis in the antecedents. Although various therapeutic options for generalized granuloma annulare are mentioned in the specialized literature, the lack of standardized guidelines is disappointing for both the physician and the patient, reflecting the rarity of reported cases. Anecdotally cited treatments include cryotherapy, laser ablation, PUVA, and photodynamic therapy. In our patient, after a session of liquid nitrogen cryotherapy that had a paradoxically unfavorable outcome, treatment with hydroxychloroquine and topical calcineurin inhibitors was initiated, resulting in a slight improvement of the lesions.

**Keywords:** generalized granuloma annulare, clinical aspects, modern therapy.

Received: 26.03.2026

Accepted: 23.04.2026

### Introduction

Granuloma annulare (GA) is a relatively uncommon inflammatory skin disorder, distinguished by the development of elevated, circular or ring-shaped lesions on the surface of the skin that can affect both children and adults. It can manifest as a localized condition or as a disseminated one. There are also less common

variations of this benign condition, including the patch, perforating and subcutaneous subtypes.

The generalized form of granuloma annulare (15% of cases) tends to affect various areas of the body, with a preference for the extremities and trunk. It is characterized by the presence of widespread papules and plaques that can be either erythematous or skin-colored. The

\* Department of Dermatology, "Victor Babeș" Clinical Hospital for Infectious Diseases, Bucharest

\*\* Department of Dermatology, "Carol Davila" University of Medicine and Pharmacy, Bucharest

characteristic ring shape occurs in two-thirds of patients. These lesions vary in size, ranging from a few millimeters to a few centimeters in diameter, being asymptomatic or pruritic.

The exact cause of GA remains unknown. Several potential factors that may trigger the development of GA have been reported, including drug exposure (allopurinol, amlodipine, diclofenac), viral infections, insect bites, vaccinations, trauma or sun exposure. GA can be potentially associated with diabetes mellitus, dyslipidemia or malignancy.

Various treatments are cited in the literature in this field, however guidelines are missing, due to the scarcity of GDA cases reported; among these, criotherapy, PUVA, pulsed dye laser and fractional photothermolysis are anecdotally cited. Hydroxychloroquine, isotretinoin, and dapsone are commonly chosen as initial therapies for GA due to their accessibility and the relatively safe profile.

### Case report

We report a case of a 63-year-old female presenting in our dermatology clinic with asymptomatic, erythematous plaques located on the trunk (anterior and posterior), upper and lower limbs for about 6 months. The lesions were annular, arciform and round, with a diameter between 0.5 - 4 cm and elevated margins (Fig. 1; Fig. 2). No other symptoms were associated. The patient is also known with coronary bypass and vasculitis in the antecedents.

Immunology testing revealed a slightly elevated C-reactive protein (CRP = 1.01 mg/dL, reference interval 0-0.3 mg/dL), while serum biochemistry showed elevated cholesterol (236 mg/dL, reference interval 0-200 mg/dL) and triglycerides (166 mg/dL, reference interval 0-150 mg/dL). Blood glucose was in the normal reference range (96 mg/dL, reference interval 70-110 mg/dL).

To confirm the diagnosis, we performed two punch biopsies from the posterior trunk and histopathological examination revealed granulomas characterized by histiocytes arranged in a palisading pattern around areas of necrobiotic collagen with mucin deposition (Fig. 3).

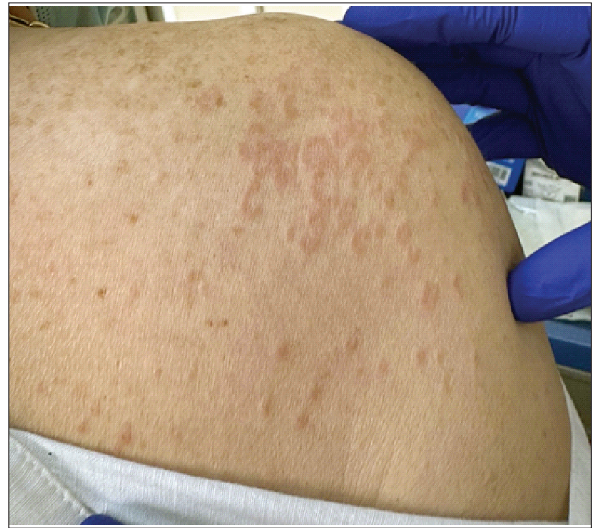

Figure 1. Multiple erythematous papules and annular plaques on the right shoulder (image from our clinic)

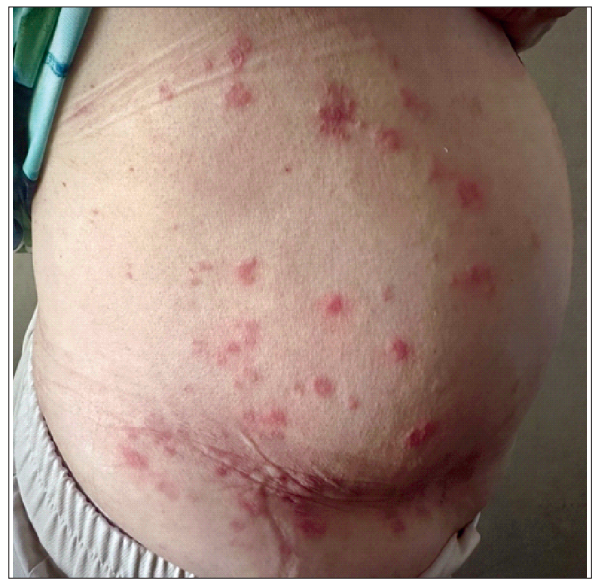

Figure 2. Erythematous plaques with elevated margins located on the anterior trunk (image from our clinic).

In the case we are presenting, following a paradoxically unsuccessful cryotherapy session with liquid nitrogen, the patient was started on treatment with hydroxychloroquine and topical calcineurin inhibitors, resulting in mild improvement of the lesions.

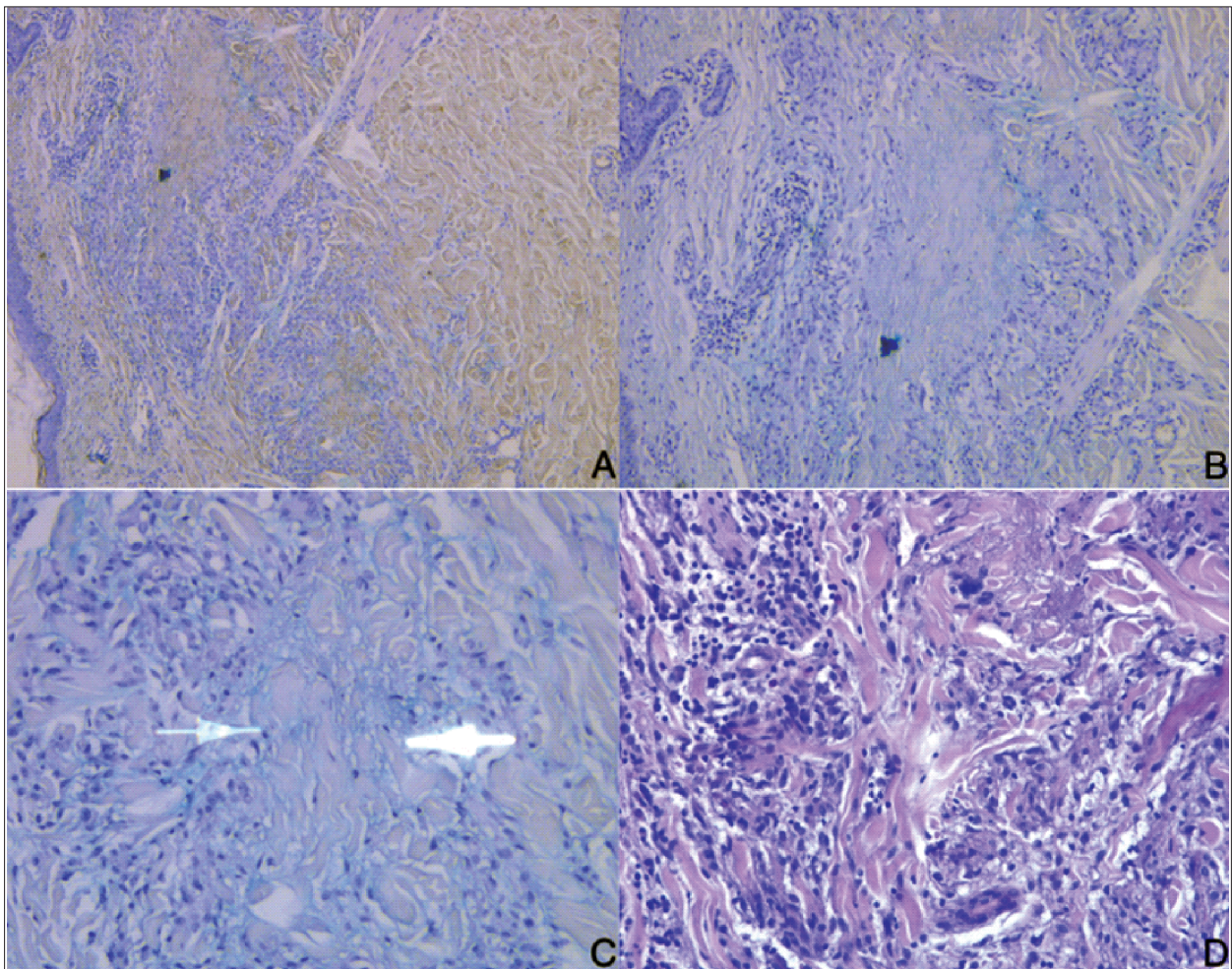


Figure 3. Granuloma annulare – epithelioid histiocytic granulomas with palisading at the periphery and rare multinucleated giant cells, centrally collagen bundles, focally degraded A. Alcian blue, 10X; B. Alcian blue 20X; C. Alcian blue, 40X; D. H&E 40X.

## Discussions

Although topical therapies effective for localized GA may also benefit generalized GA lesions, their daily use over large skin areas is often impractical. As a result, systemic treatment is generally preferred as the initial approach for generalized GA, with topical therapies used selectively for the most symptomatic or treatment-resistant areas.

Hydroxychloroquine is a commonly used systemic treatment for generalized granuloma annulare due to its immunomodulatory effects and relatively favorable safety profile. The typical adult dose of hydroxychloroquine ranges from 3

to 5 mg/kg per day. While 400 mg daily is a commonly prescribed amount, the dose should not exceed 5 mg/kg per day to reduce the risk of ocular toxicity associated with treatment. A baseline ophthalmologic evaluation is recommended before starting therapy or within the early stages of treatment. Other possible side effects are gastrointestinal distress, cutaneous drug eruptions, headaches, and cardiotoxicity.

Isotretinoin, an oral retinoid, can be prescribed for generalized GA at a typical dose of 0.5 mg/kg per day, usually for three to four months. While some patients maintained remission for over six months, others relapsed

after stopping treatment. Regarding adverse effects, isotretinoin is teratogenic being contraindicated in pregnancy, can cause mucocutaneous manifestations (xerosis, cheilitis, epistaxis and pruritus), hyperlipidemia and elevated liver enzymes.

Dapsone, a sulfone antibiotic, can be administered 100 mg/day, usually for a few weeks to four months. Although dapsone may represent a potential therapeutic option, the supporting evidence remains limited. Haematological adverse effects can occur, such as hemolysis, agranulocytosis or methemoglobinemia.

Narrowband ultraviolet B phototherapy is another alternative treatment. Clinical improvement is generally observed after use three times per week for a minimum duration of two months. It can also cause some adverse effects, such as xerosis, pruritus, erythema or photoaging.

If the disease remains refractory after these therapeutic options, the following can also be used: TNF-alpha inhibitors, cyclosporine, apremilast, oral JAK1 inhibitors, or PUVA (psoralen plus ultraviolet).

- TNF-alpha inhibitors: limited evidence suggests that adalimumab and infliximab may be effective treatments, to differentiate it from etanercept, which has not proven effective for granuloma annulare. Usual doses for adalimumab are 80 mg first dose followed by 40 mg/week and for infliximab are 5mg/kg at weeks 0, 2, 6 and every 8 weeks with improvement within two months.
- Cyclosporine has potentially serious adverse reactions (kidney failure, hepato-

toxicity, infections or malignancy), but evidence from case reports suggests a potential benefit of this treatment. Usual dose is 3 to 4 mg/kg per day with improvement within one month.

- Apremilast, an oral phosphodiesterase 4 inhibitor, is another option for refractory disease. The benefits of apremilast include its relatively good safety profile and the absence of routine laboratory monitoring. The usual adult dose of apremilast is 30 mg twice daily after an initial titration schedule.
- Oral JAK1 inhibitors: improvements in generalized GA have been reported in case studies with JAK inhibitors such as upadacitinib (15–30 mg/day), baricitinib (2–4 mg/day), abrocitinib (100–200 mg/day), and tofacitinib (5 mg twice daily) with improvement within two months.
- PUVA therapy consists of administering a photosensitizing agent followed by UVA light exposure, usually performed approximately twice per week. Adverse effects are nausea, pruritus, skin aging, and risk for cutaneous malignancies.

## Conclusions

Generalized granuloma annulare is a rare skin condition with challenging treatment. It is useful for dermatologists to consider this disease and correlate it with potential associated factors. In the case of our patient, it remains to be investigated what exactly is the cause of the disease and how the treatment response progresses.

## Bibliografie/Bibliography

1. Brodell, R. Granuloma Annulare: Epidemiology, Clinical Manifestations, and Diagnosis. UpToDate 2022, 1–62.
2. Yun, J. H.; Lee, J. Y.; Kim, M. K.; Seo, Y. J.; Kim, M. H.; Cho, K. H.; Kim, M. B.; Lee, W. S.; Lee, K. H.; Kim, Y. C.; Lee, S. J.; Choi, G. S.; Won, Y. H.; Ihm, C. W.; Yoon, T. Y. Clinical and Pathological Features of Generalized Granuloma Annulare with Their Correlation: A Retrospective Multicenter Study in Korea. *Ann. Dermatol.* 2009, 21 (2). <https://doi.org/10.5021/ad.2009.21.2.113>.
3. Lim, A. C.; Hart, K.; Murrell, D. A Granuloma Annulare-like Eruption Associated with the Use of Amlodipine. *Australas. J. Dermatol.* 2002, 43 (1). <https://doi.org/10.1046/j.1440-0960.2002.00547.x>.
4. Barbieri, J. S.; Rosenbach, M.; Rodriguez, O.; Margolis, D. J. Association of Granuloma Annulare with Type 2 Diabetes, Hyperlipidemia, Autoimmune Disorders, and Hematologic Malignant Neoplasms. *JAMA Dermatology* 2021, 157 (7). <https://doi.org/10.1001/jamadermatol.2021.1805>.

5. Stratman, E. Granuloma Annulare: Management. 2026, 1–42.
6. Hrin, M. L.; Bashyam, A. M.; Feldman, S. R.; Huang, W. W. Oral Dapsone for the Treatment of Generalized Granuloma Annulare: A Retrospective Case Series. *J. Am. Acad. Dermatol.* 2022, 86 (4). <https://doi.org/10.1016/j.jaad.2021.03.045>.
7. Pavlovsky, M.; Samuelov, L.; Sprecher, E.; Matz, H. NB-UVB Phototherapy for Generalized Granuloma Annulare. *Dermatol. Ther.* 2016, 29 (3). <https://doi.org/10.1111/dth.12315>.
8. Shupack, J.; Siu, K. Resolving Granuloma Annulare with Etanercept [4]. *Archives of Dermatology.* 2006. <https://doi.org/10.1001/archderm.142.3.394>.
9. Spadino, S.; Altomare, A.; Cainelli, G.; Franchi, C.; Frigerio, E.; Garutti, C.; Taglioni, M.; Altomare, G. F. Disseminated Granuloma Annulare: Efficacy of Cyclosporine Therapy. *Int. J. Immunopathol. Pharmacol.* 2006, 19 (2). <https://doi.org/10.1177/039463200601900219>.
10. Joshi, T. P.; Tschien, J. Apremilast in the Management of Disseminated Granuloma Annulare. *Cureus* 2021. <https://doi.org/10.7759/cureus.14918>.

Conflict de interese  
NEDECLARATE

Conflict of interest  
NONE DECLARED

*Adresa de corespondență:*

*Correspondance address:* Conf. univ. Dr. Mircea Tampa  
Department of Dermatology, "Victor Babeș" Clinical Hospital for Infectious Diseases, Bucharest.  
Department of Dermatology, "Carol Davila" University of Medicine and Pharmacy, Bucharest  
e-mail: mircea.tampa@umfcd.ro